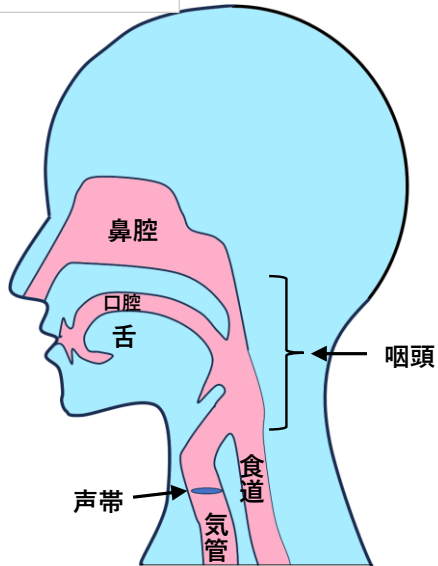
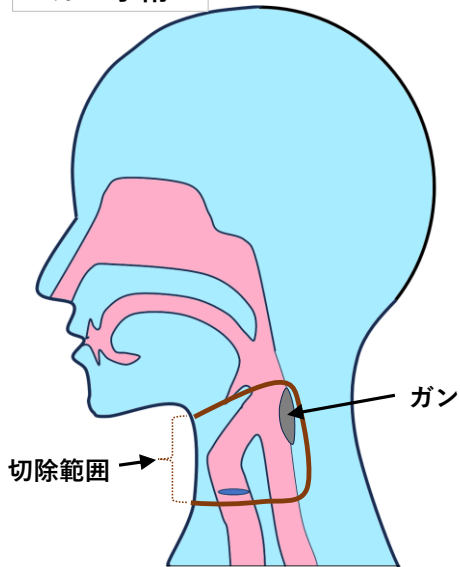


# ◆咽頭部構造の変化◆

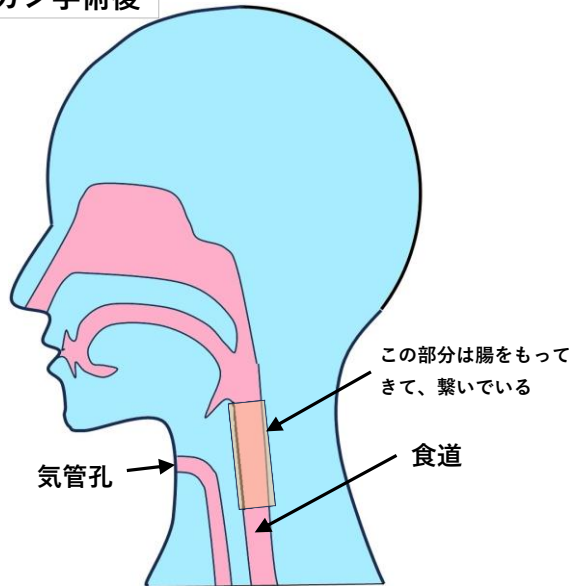
## 正常な構造



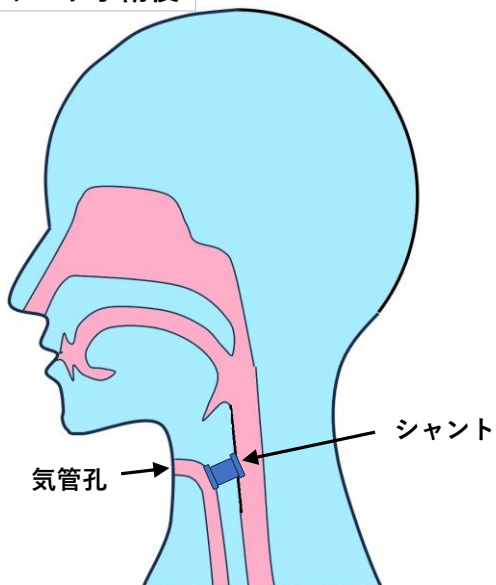
## ガン手術



## ガン手術後



## シャント手術後



## シャント発声

